EFECTIVIDAD DEL BLOQUEO LOCOREGIONAL EN ANALGESIA POSTOPERATORIA

EFRÉN GARCÍA CALO
CHUAC
H. MATERNO-INFANTIL TERESA HERRERA

SERVIZO GALEGO de SAÚDE | Complexo Hospitalario Universitario A Coruña A Coruña

HISTORIA

- 1899 → Bier. Primera anestesia raquídea
- Siglo XX → Anestesia general
- 1980 Shandling y Steward → anestesia regional combinada
- Actualidad→ Anestesia en ventilación espontánea + bloqueo regional

SEGURIDAD

- ANATOMÍA
- TÉCNICA
- COLABORACIÓN DEL PACIENTE
- CONSENTIMIENTO INFORMADO
- AJUSTAR DOSIS

CONCLUSIONS: The placement of regional anesthetic blocks in pediatric patients under GA is as safe as placement in sedated and awake children. Our results provide the first prospective evidence for the pediatric anesthesia community that the practice of placing blocks in anesthetized patients should be considered safe and should remain the prevailing standard of care. Prohibitive recommendations based on anecdote and case reports cannot be supported.

VENTAJAS

- Menos opioides
- Menos relajantes musculares
- Despertar plácido
- Disminución del estrés quirúrgico
- Menor incidencias de náuseas y vómitos
- Alta precoz

CONTRAINDICACIONES

- NEUROPATÍA PERIFÉRICA
- ALTERACIÓN DE LA COAGULACIÓN
- INFECCIÓN DEL SITIO DE PUNCIÓN
- ANOMALÍAS ANATÓMICAS
- RECHAZO POR PARTE DEL RESPONSALBE DEL MENOR

COMPLICACIONES

- PUNCIÓN DIRECTA CON LA AGUJA
- INYECCIÓN INTRANEURAL
- ISQUEMIA (VASOCONSTRICTOR)
- TOXICIDAD POR AL
- COMPRESIÓN NERVIOSA (HEMATOMA)

Pediatric Regional Anesthesia Network (PRAN): A Multi-Institutional Study of the Use and Incidence of Complications of Pediatric Regional Anesthesia

Polaner, David M. MD, FAAP[*†]; Taenzer, Andreas H. MD, MS, FAAP[‡§]; Walker, Benjamin J. MD[‖]; Bosenberg, Adrian MB, ChB, FFA[‖]; Krane, Elliot J. MD[¶#]; Suresh, Santhanam MD[**††]; Wolf, Christine MBS[‡‡]; Martin, Lynn D. MD, MBA, FAAP, FCCM[‖§§]

Anesthesia & Analgesia: December 2012 - Volume 115 - Issue 6 - p 1353–1364
doi: 10.1213/ANE.0b013e31825d9f4b
Pediatric Anesthesiology

	Total	None	Nerve stimulator	Fluoroscopy	Ultrasound
Interscalene/parascalene	80	2	16 (20%)	0	78 (98%)
Supraclavicular	164	2	22 (13%)	0	158 (96%)
Infraclavicular	40	1	11 (28%)	0	38 (95%)
Axillary	99	14	12 (12%)	1	77 (78%)
Musculocutaneous	5	2	0	0	3 (60%)
Elbow	1	0	0	0	1 (100%)
Wrist	7	7	0	0	0
Other	58	33	2 (3%)	3	19 (33%)
Totals	455	61	64 (14%)	4	375 (82%)

More than 1 technology can be used for a block, thus totals may exceed 100%.

ANESTHESIA & ANALGESIA

	Total	None	Nerve stimulator	Fluoroscopy	Ultrasound	Other
Lumbar plexus/psoas compartment	78	8	60 (77%)	9 (12%)	9 (12%)	1 (1%)
Fascia iliaca	221	166	4 (2%)	0	48 (22%)	0
Femoral	872	35	313 (36%)	1 (0.1%)	760 (87%)	0
Sciatic	413	13	195 (47%)	0	303 (73%)	0
Popliteal fossa	319	11	151 (47%)	2 (0.6%)	265 (83%)	0
Saphenous	78	9	5 (6%)	0	65 (83%)	0
Other	325	119	36 (11%)	20 (6%)	169 (52%)	0
Totals	2307	361	764 (33%)	32 (1%)	1619 (70%)	1 (0.4%)

More than 1 technology can be used for a block, thus totals may exceed 100%.

ANESTHESIA & ANALGESIA

	Total blocks	None	Nerve stimulator	Fluoroscopy	Ultrasound
Intercostal	39	8	0	0	30 (77%)
Ilioinguinal/iliohypogastric	737	158	2	3	563 (76%)
Rectus sheath	294	32	2	0	256 (87%)
Paravertebral	14	8	0	1	4 (29%)
Penile	230	224	0	0	2 (0.9%)
TAP	140	2	0	0	129 (92%)
Other	395	198	3	44	147 (37%)
Totals	1849	630	7	48	1131 (61%)

TAP = transversus abdominis plane.

ANESTHESIA & ANALGESIA

ECOGRAFÍA

- Desde 2009 la Sedar lo recomienda
- Desventajas:
  - Menor tamaño de estructuras
  - Tamaño de las sondas
- Ventajas:
  - Mayor consistencia acuosa
  - Menor calcificaciones
  - Menor profundidad
- Sondas de alta frecuencia
- Mayor eficacia de la técnica



BLOQUEOS MAS USADOS

- BLOQUEO PLEXO BRAQUIAL
- BLOQUEO CIÁTICO – CIÁTICO POPLÍTEO
- BLOQUEO FEMORAL
- BLOQUEO ILIOFASCIAL
- BLOQUEO PENEANO
- BLOQUEO ILEOINGUINAL-ILIOHIPOGÁSTRICO
- BLOQUEO DE LA VAINA DE LOS RECTOS

Bloqueos periféricos

Ilioinguinal e Iliohipogástrico	Hernia inguinal, hidrocele, quistes de cordón
+ infiltración escrotal	Orquidopexias
Dorsales del pene	Fimosis, frenillo, hipospadias leve
Paraumbilical	Hernia umbilical, epigástrica, estenosis píloro
Plexo braquial	Cirugía de EESS, bloqueo simpático continuo
N. mediano, cubital, radial	Complemento de fallos en bloqueo Plexo braquial. Cirugía correspondiente a la zona inervada
Ileofascial, Femoral	Biopsias muslo, cirugía de fémur y rodilla
Ciático	Cirugía distal a la rodilla
Auricular	Cirugía del pabellón auricular

BLOQUEO PLEXO BRAQUIAL

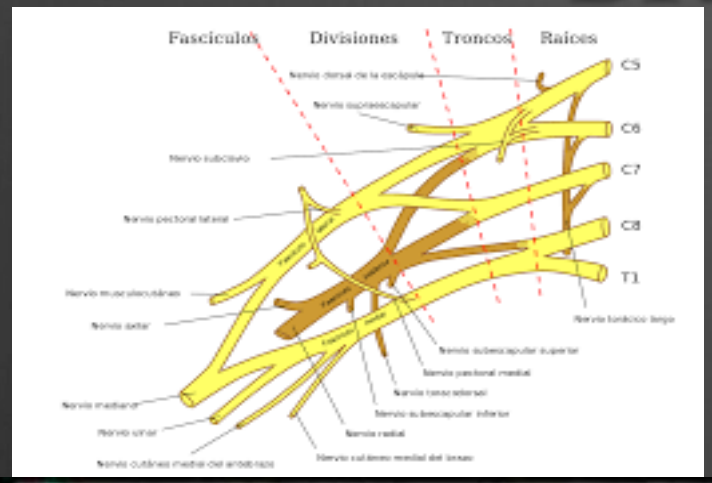

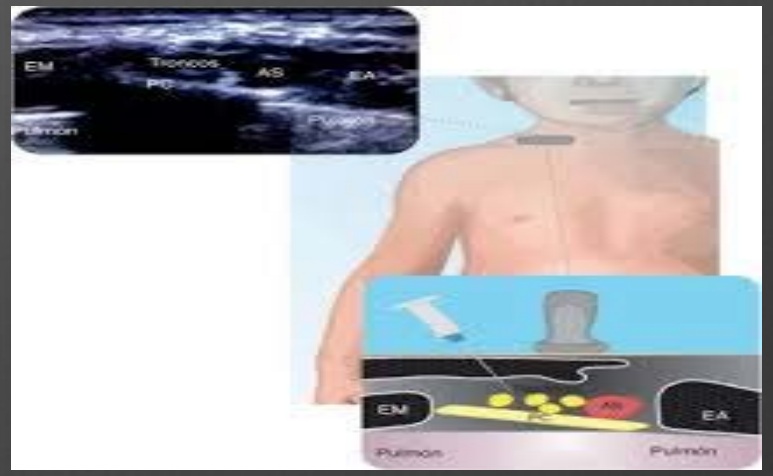

Paediatr Anaesth. 2008 Sep;18(9):838-44. doi: 10.1111/j.1460-9592.2008.02644.x. Epub 2008 Jun 9.

Ultrasound-guided supraclavicular vs infraclavicular brachial plexus blocks in children.

De José María B[1], Banús E, Navarro Egea M, Serrano S, Perelló M, Mabrok M.

BACKGROUND: Supraclavicular brachial plexus blocks are not common in children because of risk of pneumothorax. However, infraclavicular brachial plexus blocks have been described in paediatric patients both with nerve stimulation and ultrasound (US)-guidance. US-guidance reduces the risk of complications in supraclavicular brachial plexus blocks in adults.

OBJECTIVE: To compare the success rate, complications and time of performance of US-guided supraclavicular vs infraclavicular brachial plexus blocks in children.

CONCLUSIONS: (i) Ultrasound-guided supraclavicular and infraclavicular brachial plexus blocks are effective in children. (ii) There has been no pneumothorax in 40 US-guided supraclavicular brachial plexus blocks performed by anaesthesiologists already trained in US-guided regional anaesthesia using an IP technique in children > or =5 years old. (iii) In this study, the supraclavicular approach of the brachial plexus was faster to perform than the infraclavicular one.

Eficacia Analgésica del bloqueo de plexo braquial vía axilar en cirugías de ortopedia de miembros superiores en pacientes pediátricos en el Hospital Escuela Manuel de Jesús Rivera La Mascota en el período Septiembre-Octubre 2016

Rosales Barrios, Álvaro Noel and Solano Valle, Lenard Fohad and Pavón Gómez, Gabriel Gerónimo (2017) *Eficacia Analgésica del bloqueo de plexo braquial vía axilar en cirugías de ortopedia de miembros superiores en pacientes pediátricos en el Hospital Escuela Manuel de Jesús Rivera La Mascota en el período Septiembre-Octubre 2016*. Other thesis, Universidad Naciuonal Autónoma de Nicaragua, Managua.

Abstract

Como objetivo principal del estudio tenemos determinar la eficacia analgésica que posee el bloqueo de plexo braquial vía axilar en pacientes pediátricos mediante valoración con fichas de recolección y guías de observación con escalas del dolor pediátricas, las cuales nos ayudaron a determinar distintos parámetros de la investigación, la cual fue llevada a cabo en el hospital Manuel de Jesús rivera la mascota. Este es un estudio cuantitativo, descriptivo , observacional, según el tiempo prospectivo y de cohorte trasversal, en relación a la población está constituida por todos los pacientes pediátricos sometidos a cirugías de miembros superior, la muestra fue de 16 pacientes el cual lo conformo 12 pacientes masculinos y 4 pacientes femeninas, el grupo de edad más frecuente en dicha investigación fueron las edades que oscilaron de 1-3 años con 31.3% y un segundo grupo de 6-9 años con el mismo porcentaje 31.3%. No se presentaron complicaciones de la técnica pero la variable hemodinámica más representativa fue la taquicardia la cual la presentaron 3 pacientes los cuales equivalen al 19%, se utilizó dosis mcg/kg/min de fentanil para inducción anestésica las cuales oscilaron entre 0.016-0.026 y una dosis minina de 0.013 destacándose el ahorro de opioides, en el caso de los halogenados la concentración alveolar mínima fue de 0.46% como concentración mínima y 1.10% como pico más alto

BLOQUEO FEMORAL

- ANALGESIA ANTERIOR EEII (HASTA RODILLA)
- BLOQUEO NO COMPLETO
- IQ → FÉMUR. RODILLA
- REFERENCIA: A. – V. FEMORAL
- DOSIS 0,3-0,5 ML/KG

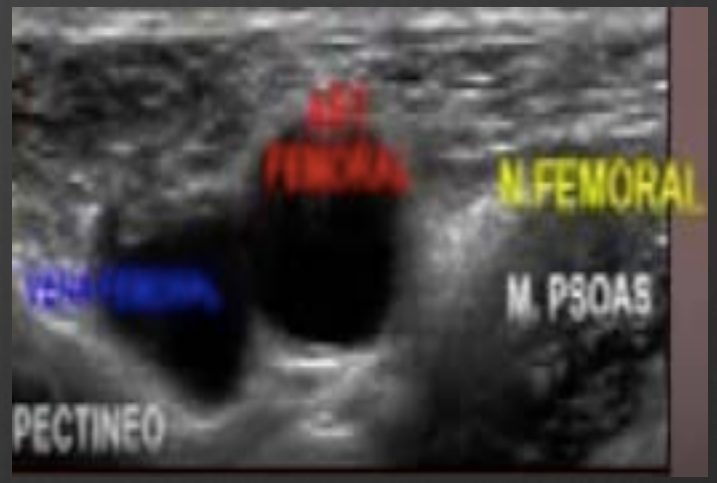

BLOQUEO ILIOFASCIAL

- DALENS 1987
- TRES EN UNO.
- BLOQUEO INTERFASCIAL
- DOSIS 0,5-1 ML/KG

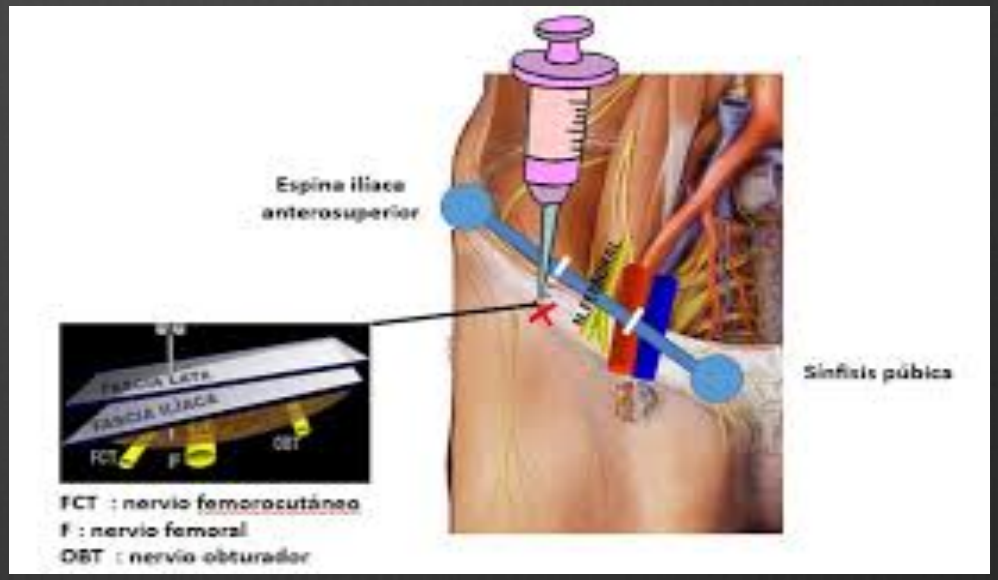

BLOQUEO CIATÍCO

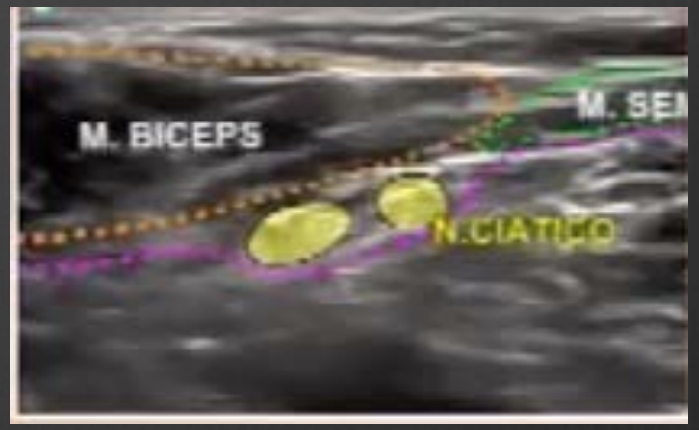

J Clin Anesth. 2010 Jun;22(4):241-5. doi: 10.1016/j.jclinane.2009.07.009.

Ultrasound-guided proximal and distal sciatic nerve blocks in children.

van Geffen GJ[1], Pirotte T, Gielen MJ, Scheffer G, Bruhn J.

MEASUREMENTS: The injected amount of local anesthetic was noted. Based on the spread of local anesthetic, prediction for successful block was made. Complications, adverse effects, postoperative pain scores, and parent satisfaction scores were noted.

MAIN RESULTS: 21 proximal sciatic nerve blocks (12 single-injection and 9 continuous blocks) and 35 distal sciatic nerve blocks (17 single-injection, 6 bilateral single-injection, 4 continuous, and one bilateral continuous block) were performed. A mean initial dose of 0.25 mL.kg(-1) of ropivacaine 0.375% was injected. A successful block was obtained in all children. Excellent postoperative pain relief was obtained. All parents were satisfied with the postoperative pain relief. No complications occurred.

CONCLUSION: Ultrasonography is useful in the identification of the sciatic nerve and it facilitates needle and catheter placement for proximal and distal nerve blocks in children.

Ultrasonographic guidance for sciatic and femoral nerve blocks in children†

U. Oberndorfer[1], P. Marhofer[1], A. Bösenberg[2], H. Willschke[1], M. Felfernig[1], M. Weintraud[1], S. Kapral[1] and S. C. Kettner[1]*

[1]*Department of Anaesthesia and Intensive Care Medicine, Medical University Vienna, Währinger Gürtel 18–20, A-1090 Vienna, Austria.* [2]*Department of Anaesthesia and Intensive Care Medicine, University of Cape Town, Red Cross Children Hospital, Klipfontein Road, Rondebosch 7700, South Africa*

**Corresponding author. E-mail: stephan.kettner@meduniwien.ac.at*

Results. Two blocks in the nerve stimulator group failed. There were no failures in the ultrasound group. The duration of analgesia was longer in the ultrasound group mean (SD) 508 (178) *vs* 335 (169) min ($P<0.05$). The volume of local anaesthetic in sciatic and femoral nerve blocks was reduced with ultrasound compared with nerve stimulator guidance [0.2 (0.06) *vs* 0.3 ml kg^{-1} ($P<0.001$) and 0.15 (0.04) *vs* 0.3 ml kg^{-1} ($P<0.001$), respectively].

Conclusions. Ultrasound guidance for sciatic and femoral nerve blocks in children increased the duration of sensory blockade in comparison with nerve stimulator guidance. Prolonged sensory blockade was achieved with smaller volumes of local anaesthetic when using ultrasound guidance.

BLOQUEOS TRONCULARES

Beyond the caudal: truncal blocks an alternative option for analgesia in pediatric surgical patients

Jodi-Ann Oliver and Lori-Ann Oliver

Purpose of review
To discuss and compare the more commonly used truncal blocks with neuraxial techniques in children undergoing a variety of thoracic, abdominal and urological procedures.

Recent findings
Owing to the advent of ultrasonography and its increasing use in regional anesthesia, there has been a renewed interest in implementing these techniques in children for intraoperative and postoperative pain management.

Summary
The use of regional anesthesia particularly with ultrasound guidance is an integral part of pain management during the intraoperative and postoperative period in children who undergo surgery. Its use is essential in improving patient pain control and overall satisfaction as well as decreasing hospital stay and reducing hospital admission after surgery. Truncal blocks serve as an excellent alternative to neuraxial blockade, in patients who have a contraindication to neuraxial blockade, patients undergoing a unilateral procedure and those in an outpatient ambulatory setting undergoing routine procedures, wherein the adverse effects of neuraxial blockade such as motor weakness, difficulty ambulating, urinary retention, increased nausea and vomiting, may delay same day discharge.

ILIOINGUINAL

- N. ILIOHIPOGÁSTRICO. N.ILIOINGUINAL. N. GENITOFEMORAL. N. INTERCOSTAL T11-T12
- INDIACIONES: HERNIORRAFIA. HIDROCELE. CRIPTORQUÍDEA
- OBLICUO INTERNO-TRANSVERSO
- DOSIS 0,2 ML/KG

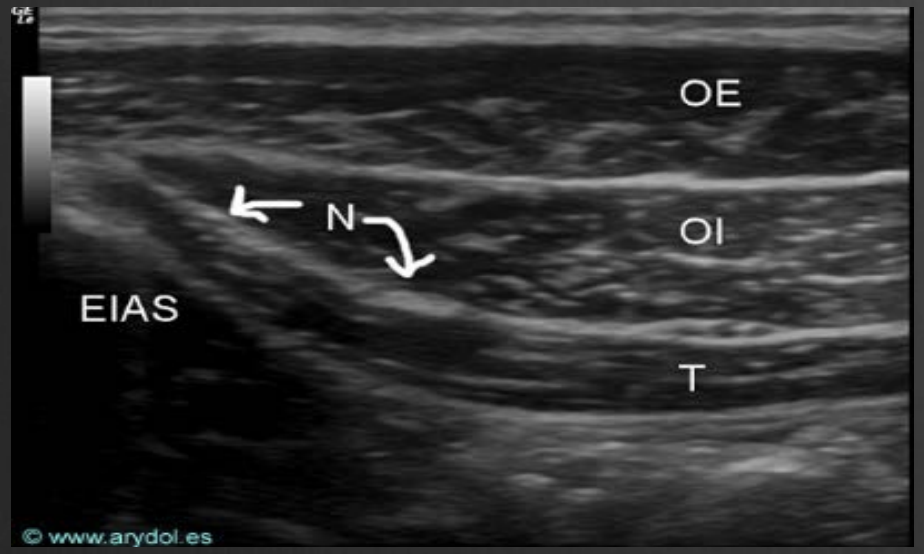

Anesth Analg. 2008 Jan;106(1):89-93, table of contents. doi: 10.1213/01.ane.0000287679.48530.5f.

Ilioinguinal/iliohypogastric blocks in children: where do we administer the local anesthetic without direct visualization?

Weintraud M[1], Marhofer P, Bösenberg A, Kapral S, Willschke H, Felfernig M, Kettner S.

BACKGROUND: Ultrasonographic observation of peripheral nerve blocks enables direct visualization of the spread of local anesthetic around the targeted nerves. Similarly, ultrasonography may be used to determine the site of local anesthetic placement when landmark-based techniques are used. We performed a study to determine the actual location of local anesthetic when ilioinguinal/iliohypogastric nerve blocks are performed using landmark-based techniques in children in an attempt to explain a failed block.

METHODS: After induction of general anesthesia (1 minimum alveolar anesthetic concentration halothane and laryngeal mask airway), 62 children scheduled for inguinal surgery received an ilioinguinal/iliohypogastric nerve block based on standard anatomical landmarks. Ultrasonography was then used to determine the actual location of local anesthetic placement. The anesthesiologist performing the block was blinded to the ultrasonographic investigation. Successful blocks were recorded either when the local anesthetic surrounded the nerves or were based on clinical signs after skin incision.

RESULTS: In 14% of the blocks, the local anesthetic was administered correctly around the nerves resulting in successful blocks. In the remaining 86%, the local anesthetic was administered in adjacent anatomical structures (iliac muscle 18%, transverse abdominal muscle 26%, internal oblique abdominal muscle 29%, external oblique abdominal muscle 9%, subcutaneous 2%, and peritoneum 2%), and 45% of these blocks failed.

CONCLUSION: Accurate placement of local anesthetic around the ilioinguinal/iliohypogastric nerves in children is seldom possible when landmark-based techniques are used. In the majority of patients, the local anesthetic was inaccurately placed in adjacent anatomical structures with unpredictable block results.

Improved Perioperative Analgesia with Ultrasound-Guided Ilioinguinal/iliohypogastric Nerve or Transversus Abdominis Plane Block for Open Inguinal Surgery: A Systematic Review and Meta-Analysis of Randomized Controlled Trials

Abstract

Ilioinguinal/iliohypogastric (II/IH) nerve and transversus abdominis plane (TAP) blocks are both effective perioperative analgesic techniques for open inguinal surgery. Ultrasound-guided II/IH nerve and TAP blocks have been increasingly utilized in patients for perioperative analgesia. Yet the use of ultrasound has not been fully evaluated. We conducted this meta-analysis to evaluate the clinical efficacy of ultrasound-guided II/IH nerve or TAP blocks for perioperative analgesia in patients undergoing open inguinal surgery. A systematic search of seven databases was conducted from database inception to March 5, 2015. Randomized controlled trials (RCTs) comparing the clinical efficacy of either ultrasound-guided or landmark-based techniques to perform II/IH nerve and TAP blocks for perioperative analgesia in patients with open inguinal surgery were included. Two reviewers independently (and in duplicate) screened abstracts and full texts. We constructed random effects models to pool standardized mean difference (SMD) for continuous outcomes and odds ratio (OR) for dichotomized outcomes. Heterogeneity between studies was estimated by I2statistic. One hundred thirty-nine articles were identified and among them 4 articles were eligible for the final analysis. Ultrasound-guided II/IH nerve or TAP blocks were associated with reduced use of intraoperative additional analgesia with OR=0.21 (95% CI: 0.09 to 0.49; $p<0.001$; $I^2= 0.00\%$) and significant reduction of pain scores during day-stay with SMD=-0.96 (95% CI: -1.68 to -0.24; $p<0.001$; I2=88.3%). The use of rescue drug was also significantly lower in the ultrasound-guided group (OR=0.16; 95% CI: 0.06, 0.40; $p<0.001$, $I^2=10.2\%$). In conclusion, the use of ultrasound-guidance to perform an II/IH nerve or a TAP block was associated with improved perioperative analgesia in patients following open inguinal surgery compared to landmark-based methods.

Keywords: Ultrasound; Ilioinguinal/iliohypogastric nerve; Inguinal surgery

BLOQUEO VAINA DE LOS RECTOS

- FERGUSON Y COURREGES
- NERVIOS INTERCOSTALES T9-T11
- HERNIA UMBILICAL.
- MUSCULO RECTO DEL ABDOMEN
- BLOQUEO SEGMENTARIO UNILATERAL
- DOSIS 0,2 ML/KG

Paediatr Anaesth. 1996;6(6):463-6.

The rectus sheath block in paediatric anaesthesia: new indications for an old technique?

Ferguson S[1], Thomas V, Lewis I.

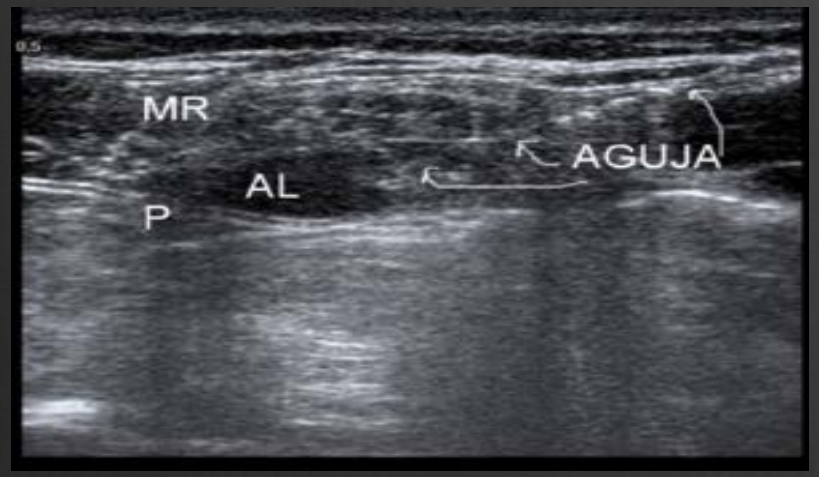

Br J Anaesth. 2011 Nov;107(5):790-5. doi: 10.1093/bja/aer263. Epub 2011 Aug 19.

Prospective randomized observer-blinded study comparing the analgesic efficacy of ultrasound-guided rectus sheath block and local anaesthetic infiltration for umbilical hernia repair.

Gurnaney HG[1], Maxwell LG, Kraemer FW, Goebel T, Nance ML, Ganesh A.

RESULTS: Fifty-two patients (26 in each group) completed the study. There was a statistically significant difference in the perioperative opioid medication consumption between the LAI group [mean: 0.13 mg kg(-1), confidence interval (0.09-0.17 mg kg^{-1})] and the RSB group [mean: 0.07 mg kg^{-1}, confidence interval (0.05-0.09 mg kg^{-1})] (P=0.008). When we compared the postoperative opioid consumption between the LAI group [mean: 0.1 mg kg^{-1}, 95% confidence interval (0.07-0.13 mg kg^{-1})] and the RSB group [mean: 0.07 mg kg(-1), 95% confidence interval (0.05-0.09 mg kg^{-1})] (P=0.09), there was a trend towards statistical significance between the two groups. The difference in time to rescue analgesic administration between the RSB group [49.7 (36.9) min] and the LAI group [32.4 (29.4) min] was not statistically significant (P=0.11).

TAP

- DESCRITO RAFI
- RAMAS ANTERIORES T6-L1
- OBLICUO INTERNO-TRANSVERSO
- CIRUGÍA ABDOMINAL Y UROLOGICA
- DOSIS 0,2-0,3 ML/KG

Transversus Abdominis Plane Block in Children: A Multicenter Safety Analysis of 1994 Cases from the PRAN (Pediatric Regional Anesthesia Network) Database

Long, Justin B. MD*; Birmingham, Patrick K. MD*; De Oliveira, Gildasio S. Jr MD, MSCI†; Schaldenbrand, Katie M. MPH*; Suresh, Santhanam MD*

Anesthesia & Analgesia: August 2014 - Volume 119 - Issue 2 - p 395–399
doi: 10.1213/ANE.0000000000000284
Pediatric Anesthesiology: Research Report

	Subjects (n = 1994)
Age (mo)	95 (27–156)
Gender	
Male	1099
Female	895
Weight (kg)	26.4 (12.9–48.3)
ASA physical status class	
I	723
II	711
III	517
IV	43
Calendar year of block performance	
2007	4
2008	32
2009	130
2010	449
2011	739
2012	640
Anesthetic technique used with the block	
None (awake)	7
Sedation	11
General anesthesia without muscle paralysis	883
General anesthesia with muscle paralysis	1093
Ultrasound	
Yes	1887
No	49
Not determined	58
Local anesthetic type	
Bupivacaine	1448
Ropivacaine	546

BNDP

- RAMA TERMINAL DEL N. PUDENDO
- EVITAR ROPIVACAINA
- EVITAR EL USO DE VASOCONSTRICTOR
- 0,1-0,2 ML/KG
- COMPLICACION: HEMATOMA

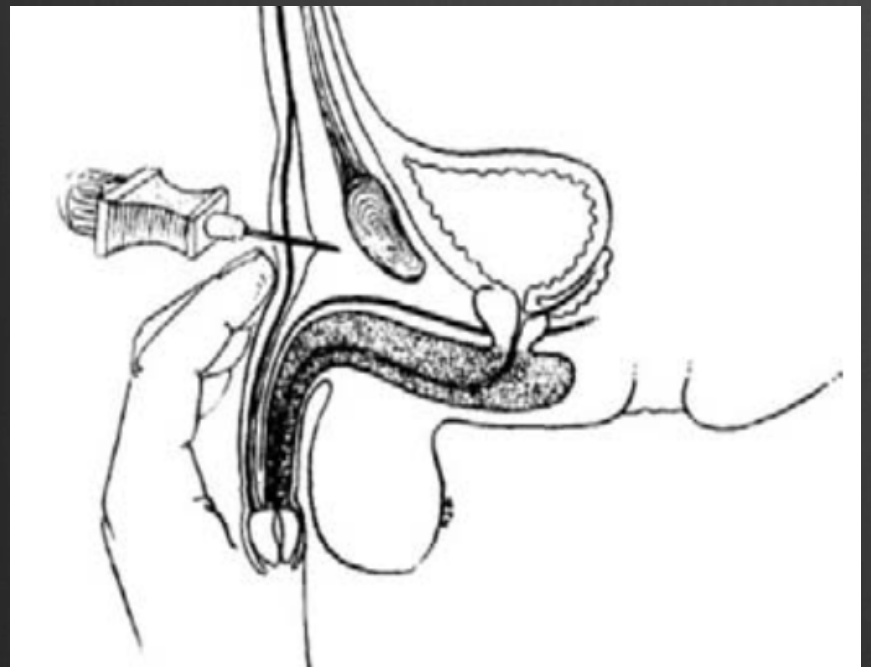

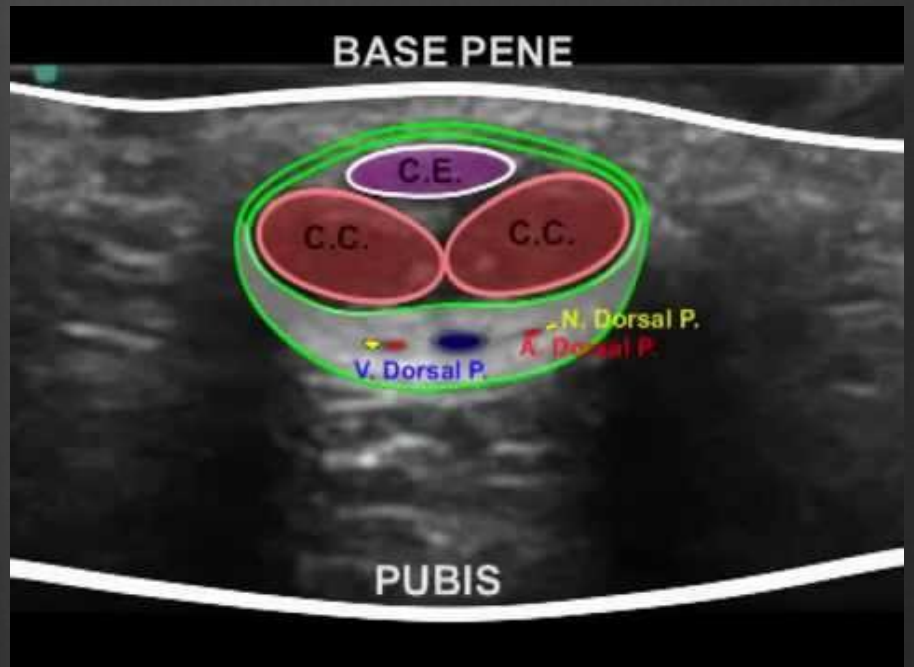

ANALGESIA POSOPERATORIA MEDIANTE BLOQUEO DEL NERVIO DORSAL DEL PENE EN CIRUGIA UROLOGICA PEDIATRICA

Dr. Luis Cantillo Hernández[1], Dr. MSc. Carlos Alberto Díaz Pérez[2], Dr. William Louis Alvarez[3], Dr. Lizardo Guilarte González[1], Dr. Narciso Creme Osorio[1]. Dra. Marlene de los Santos Correoso Bravo[1].

RESUMEN

Lograr una adecuada analgesia posoperatoria en la cirugía pediátrica se ha convertido en uno de los objetivos más importantes de la anestesia contemporánea, por lo que representa para evitar complicaciones posoperatorias relacionadas con el dolor y para lo cual se emplean diferentes métodos, entre éstos el bloqueo de los nervios sensitivos. Se realizó un estudio descriptivo para evaluar la efectividad del bloqueo del nervio dorsal del pene (BNDP) en 244 pacientes intervenidos de forma electiva o de urgencia en la unidad quirúrgica del Hospital Pediátrico Docente "Pedro Agustín Pérez", en el periodo de enero de 2005 a enero de 2007. Para evaluar el dolor posoperatorio se utilizaron elementos de la escala de evaluación del dolor de la Unidad de Tratamiento del Dolor – UCIP del Hospital del Niño Jesús en Madrid, España, y de la escala de Hannallah y cols. La mayoría de los pacientes, 113 (46,3%), estaban comprendidos en el grupo de edades de 1 – 5 años, y la fimosis, en 150 (61,5%) pacientes, fue el diagnóstico preoperatorio más común. El BNDP mostró ser una técnica segura y eficaz. Sólo un paciente presentó complicación de la técnica y 123 (50,4%) no presentaron dolor en el posoperatorio.

Manejo anestésico para circuncisión en niños: Bloqueo del nervio dorsal del pene *versus* anestesia general

Dra. Lorena López-Maya,* Dr. Francisco Lina-Manjarrez,** Dr. Francisco Fuentes-Ramos***
Dra. Blanca Flor Espíndola-Flores,**** Dra. Lorena Monserrat Lina-López*****

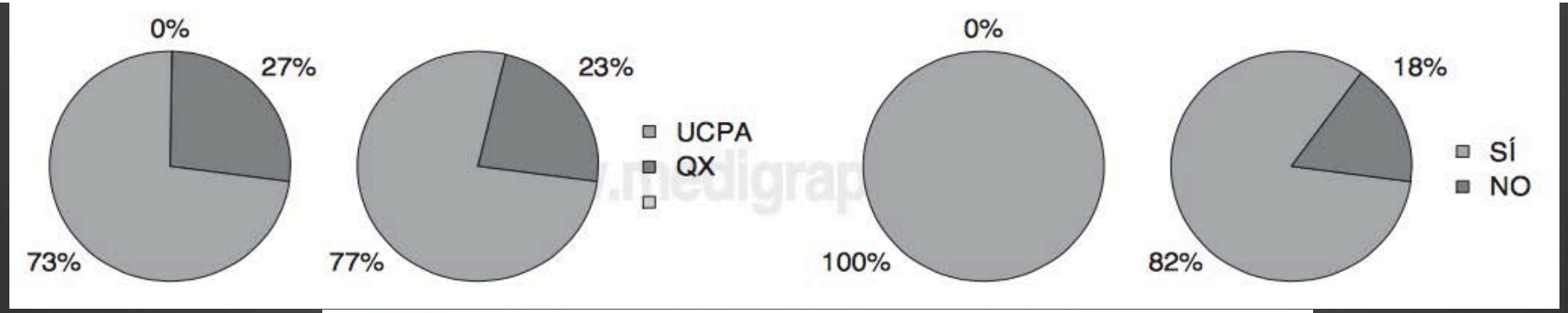

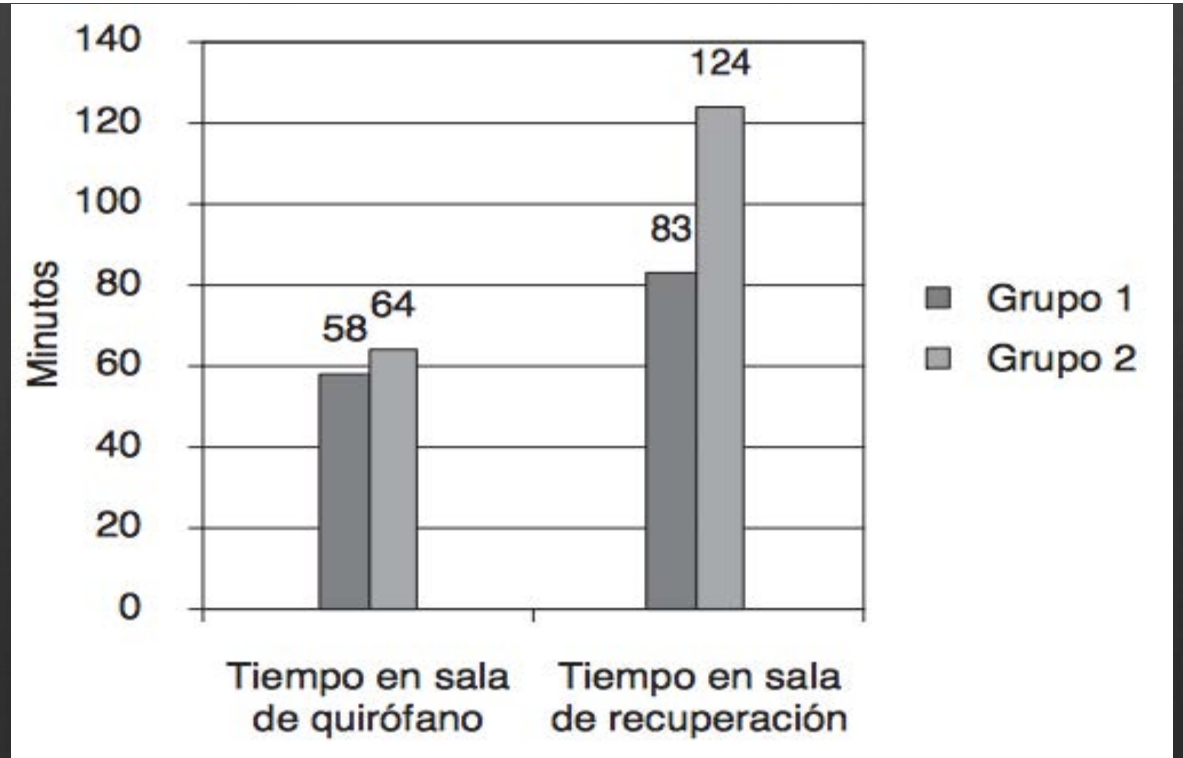

LOS BNP IGUALAN EN EFECTIVIDAD A LOS NEUROAXIALES CON MENOS MORBIMORTALIDAD PERO CON UNAS INDICACIONES CONCRETAS

MUCHAS GRACIAS